



R. Martina
I. Cioffi
M. Farella
P. Leone
P. Manzo
G. Matarese
M. Portelli
R. Nucera
G. Cordasco

Authors' affiliations:

R. Martina, I. Cioffi, M. Farella, P. Leone, P. Manzo, Department of Oral Sciences, Section of Orthodontics and Temporomandibular Disorders, University of Naples Federico II, Naples, Italy
M. Farella, Department of Oral Sciences, Discipline of Orthodontics, University of Otago, Dunedin, New Zealand
G. Matarese, M. Portelli, R. Nucera, G. Cordasco, University of Messina, School of Dentistry, Messina, Italy

Correspondence to:

Iacopo Cioffi
Department of Oral Sciences, Section of Orthodontics and Temporomandibular Disorders
University of Naples Federico II
Via Pansini 5
80131 Napoli
Italy
E-mails: iacopo.cioffi@gmail.com;
iacopo.cioffi@unina.it

Date:

Accepted 13 February 2012

DOI: 10.1111/j.1601-6343.2012.01543.x

© 2012 John Wiley & Sons A/S

Transverse changes determined by rapid and slow maxillary expansion – a low-dose CT-based randomized controlled trial

Martina R., Cioffi I., Farella M., Leone P., Manzo P., Matarese G., Portelli M., Nucera R., Cordasco G. Transverse changes determined by rapid and slow maxillary expansion – a low-dose CT-based randomized controlled trial *Orthod Craniofac Res* 2012;**15**:159–168. © 2012 John Wiley & Sons A/S

Structured Abstract

Objectives – To compare transverse skeletal changes produced by rapid (RME) and slow (SME) maxillary expansion using low-dose computed tomography. The null hypothesis was that SME and RME are equally effective in producing skeletal maxillary expansion in patients with posterior crossbite.

Setting and Sample Population – This study was carried out at the Department of Oral Sciences, University of Naples Federico II, Italy. Twelve patients (seven males, five females, mean age \pm SD: 10.3 \pm 2.5 years) were allocated to the SME group and 14 patients (six males, eight females, mean age \pm SD: 9.7 \pm 1.5 years) to the RME group.

Materials and Methods – All patients received a two-band palatal expander and were randomly allocated to either RME or SME. Low-dose computed tomography was used to identify skeletal and dental landmarks and to measure transverse maxillary changes with treatment.

Results – A significant increase in skeletal transverse diameters was found in both SME and RME groups (anterior expansion = 2.2 \pm 1.4 mm, posterior expansion = 2.2 \pm 0.9 mm, pterygoid expansion = 0.9 \pm 0.8 mm). No significant differences were found between groups at anterior (SME = 1.9 \pm 1.3 mm; RME = 2.5 \pm 1.5 mm) or posterior (SME = 1.9 \pm 1.0 mm; RME = 2.4 \pm 0.9 mm) locations, while a statistically significant difference was measured at the pterygoid processes (SME = 0.6 \pm 0.6 mm; RME = 1.2 \pm 0.9 mm, p = 0.04), which was not clinically relevant.

Conclusion – Rapid maxillary expansion is not more effective than SME in expanding the maxilla in patients with posterior crossbite.

Key words: low-dose computed tomography; palatal expansion; randomized controlled trial

Introduction

Unilateral or bilateral posterior crossbite (PXB) is a common malocclusion in primary and early mixed dentition. Previous reports suggest that it occurs in 8–20% of children (1, 2). Treatment is recommended in growing patients to improve occlusal relationships (3, 4), to prevent the development of mandibular skeletal asymmetries (5), and to improve jaw function (6). PXB is frequently associated with a maxillary transverse deficiency (3). Thus, maxillary expansion is often advocated, which can be achieved using several therapeutic approaches (7–9).

In growing patients, rapid maxillary expansion (RME) and slow maxillary expansion (SME) are routinely used, whereas in adults, surgically assisted RME is the treatment of choice.

The biological and clinical effects of RME and SME have been investigated in several studies (9–13). RME occurs by heavy and continuous forces, applied in short lapses of time, known to produce immediate significant effects on maxillary transverse widths. In contrast, SME occurs by more intermittent and lower forces that are applied over longer periods. According to the literature, both expansion modalities appear to produce transverse changes of the maxilla (3, 14–16).

In recent decades, RME has gained preference as the treatment of choice for PXB. However, the side effects, such as reported pain, relapse of the expansion, tipping of the molars, bone loss, gingival recession, and root resorption, have lead some clinicians to prefer SME. SME is commonly thought to produce less tissue resistance around the circum-maxillary structures and, therefore, improve bone formation in the inter-maxillary suture, reducing the force-related side effects of RME (15). Currently, the choice among the two expansion modalities relies on clinical experience and attitude of the practitioner because of the lack of good scientific evidence (i.e., randomized controlled trials comparing the two treatment modalities).

The use of novel imaging techniques in the craniofacial region as well as the availability of new software for three-dimensional rendering allows for high precision and accuracy when measuring the distances between skeletal land-

marks and low radiation exposure for the patient (17–19). The purpose of this study was to compare the transverse skeletal changes determined by RME and SME by means of low-dose computed tomography (CT). The null hypothesis was that SME and RME were equally effective in increasing skeletal maxillary transverse widths in growing patients affected with posterior crossbite.

Material and methods

The study was a randomized controlled trial. The power analysis was based upon previous estimates of RME transverse skeletal effects (20) and indicated that 12 patients were needed for each treatment group (difference to detect ≥ 2.5 mm, SD = 2.0 mm, $\alpha = 0.05$, power 80%).

Patients up to 13 years old (males) and 12 years old (females) who were seeking orthodontic treatment were screened by a clinical instructor (PM) of the Postgraduate Programme in Orthodontics at the Department of Orthodontics, University of Naples Federico II, Italy, between May 2006 and October 2007. Subjects with erupted upper permanent first molars and unilateral or bilateral molar full cusp PXB whose parents were willing to participate in the study were included. Patients with severe periodontal disease (periodontal probing > 4 mm) measured at permanent first upper molars, congenital syndromes, defects, or previous orthodontic treatment were excluded.

Enrolled subjects were allocated to the two treatment groups, that is, RME or SME, by a balanced block randomization using gender as stratifying factor. A single operator (PL) allocated the patients by means of a custom-made JavaScript and was responsible for the allocation concealment, that is, the allocation was disclosed only when a new patient was enrolled in the trial. The Institutional Review Board and the local Ethics Committee approved this study. Informed consent was provided by the patient's parents.

Clinical protocol

For each patient, the medical and orthodontic histories, intraoral and extraoral photographs, CT

data, and dental casts were collected prior to placement of the appliance (T0 time).

A two-band palatal expander was used. The appliance was banded to the maxillary first permanent molars (TBE, Two-Band Expander, Fig. 1A) only and did not have any extended arm. The expander jackscrew was localized very close to the posterior boundaries of the maxilla and as close as possible to the palatal vault to enable the force to be delivered at the same heights as the centers of resistance of the maxillary first molars (Fig. 1B), and as close as possible to the pterygo-maxillary suture, to produce orthopedic effects in the posterior area of the maxilla. The appliance was placed using a glass ionometer cement (Multi-Cure Glass ionomer Cement; Unitek, Monrovia, CA, USA) following the supplier's instructions within 3 weeks from initial records.

In the RME group, the screw was initially turned eight times (2.0 mm screw activation) at chair side two hours after curing. Thereafter, the patients' parents were trained to turn the screw three times

per day (0.75 mm activation per day). In the SME group, the screw was turned twice a week (0.50 mm activation per week). During the expansion phase, RME subjects were monitored once a week, while SME patients were monitored once every 2 weeks. Each patient was provided with a custom-made diary and was instructed to report the appliance adjustments. The diary was checked at each visit by the clinical examiner to evaluate patient compliance.

In both groups, the jackscrew was activated until a 2-mm molar transverse overcorrection was achieved. After the active expansion phase, the screw was locked with light-cure flow composite (Premise Flowable; Kerr Corporation, Orange, CA, USA). Seven months after appliance positioning (T1), the palatal expander was removed, and patients underwent a second CT scan using the same parameters and condition of the previous exam. All clinical procedures were administered by a single operator (PM), who was not blinded to patient allocation.

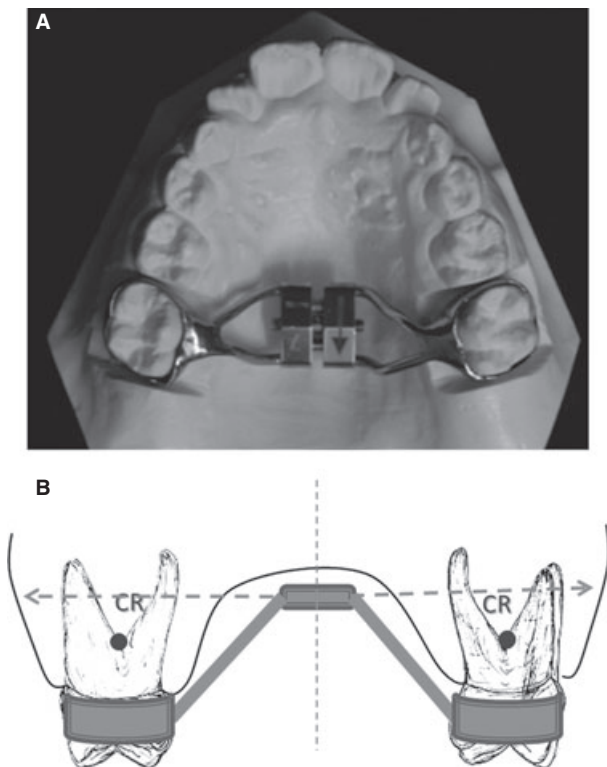


Fig. 1. (A) Two-band palatal expander. (B) The expander jackscrew was localized very close to the posterior boundaries of the maxilla and as close as possible to the palatal vault so that the force could be delivered at least at the same height of the centers of resistance of the first upper molars. Dotted line: line of action of the force delivered from the screw.

Computed tomography

For this study, a multislice CT scanner was used (Mx 8000 IDT6 Multislice; Philips medical imaging). CT images were obtained with a low-resolution/low-dose modality (17, 21) using the following parameters: slice thickness 1.3 mm, Index 1.3, Pitch 1, Mass 28, Voltage 80 kV. The field of view was limited between the infraorbital foramina and the inferior edge of the most caudal maxillary teeth for each patient. The voxel size was set at $0.35 \times 0.35 \times 1.30$ mm. Mean scanning time was 10.6 s. These settings have been shown to reduce the dose absorption for patients while providing good image quality (21–23). To ensure accurate head positioning, patients were scanned in a supine position with the Frankfurt plane perpendicular to the scanning table. The head was supported by means of two bearing pillows. A gutta-percha landmark was glued on the nasal philtrum along the longitudinal CT light beam perpendicular to the bipupillar plane to avoid head rotations.

Patient data were stored as DICOM (Digital Imaging and COmmunications in Medicine) files.

Thereafter, they were imported to software (Materialise Mimics 8.1, Leuven, Belgium) for post-processing.

Measurements

To construct a set of reference planes, two skeletal landmarks were primarily identified in the CT scans: the oval point right and left (**OVPr/OVPl**), which were defined as the most posterior points of the right and left oval foramina in the cortex of the sphenoid, at its middle cranio-caudal height. These points were primarily localized in the original coronal CT slices. A segment connecting OVPr and OVPl was then constructed. The original axial CT slices were oriented according to the segment OVPr – OVPl using the software.

A set of reference planes was then constructed as follows (Fig. 2):

Sagittal reference plane (SrPL): The sagittal CT slice passing through the middle point of the segment OVPr-OVPl.

Axial reference plane (AxrPL): The most caudal point of the clivus sphenoidalis (Basion – Ba) was localized on SrPL. The plane resulting from the 45° clockwise rotation of the axial plane passing through OVPr, OVPl, and Ba was considered as the axial reference plane (AxrPL).

Coronal reference plane (CORPL): The plane passing through OVPr-OVPl and perpendicular to AXrPL.

These reference planes were used to correct minimal changes in head positioning.

For each patient, a set of reproducible skeletal and dental landmarks were localized in coronal,

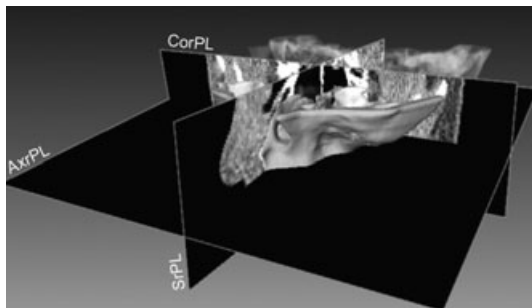


Fig. 2. Set of reference planes. Sagittal reference plane (SrPL), axial reference plane (AxrPL), coronal reference plane (CORPL).

axial, and sagittal CT slices (Fig. 3) by a single operator (RN), blinded to patient allocation, as follows:

RPyP: Right piriform point. The most lateral and caudal point of the nasal piriform aperture, at the boundary with the palatal cortex. This landmark was primarily identified in coronal CT slices passing through the anterior edge of the nasopalatine foramen within the palatal cortex. **LPyP:** Analogue to RPyP, left side.

RPaFoP: Right palatine foramen point. The most posterior point of the right greater palatine foramen in the maxilla within the palatal cortex. **LPaFoP:** Analogue to RPaFoP, left side.

PtR. Pterygoideous right. The most caudal point of the apex of the right pterygoid process of the sphenoid. **PtL.** Pterygoideous left. Analogue to PtR, left side.

CR: Cuspid right. Mesio-palatal cusp tip of the right maxillary first molar. **CL:** Cuspid left. Mesio-palatal cusp tip of the left maxillary first molar.

AR: Apex right. Apex of the palatal root of the right maxillary first molar. **AL:** Apex left. Apex of the palatal root of the left maxillary first molar.

The following distances were measured perpendicular to CorPL and SrPL at T0 and T1 by a single examiner (RN), who was blinded to patient allocation (i.e., the names of the patients and the allocation group were not included in the dataset) by means of software (Materialise mimics 8.1, Leuven, Belgium).

Skeletal measurements (Fig. 3A–C):

- Anterior maxillary expansion: RPyP-LPyP
- Posterior maxillary expansion: RPaFoP-LPaFoP
- Pterygoid expansion: PtR-PtL

Dentoalveolar measurements (Fig. 3D):

- Molar expansion: at molar cusp, CR-CL; at palatal root apex, AR-AL
- Molar tipping: difference between (AR-AL) and (CR-CL)

Statistical analysis

Paired Student's *t*-tests were used to test differences within groups. T1–T0 between groups

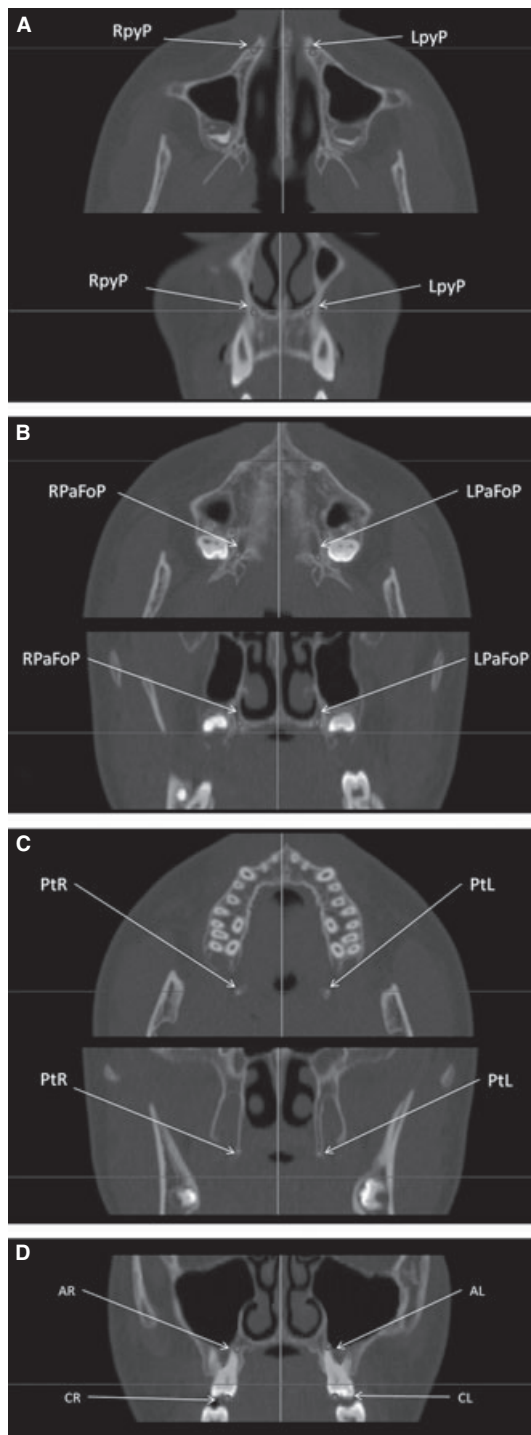


Fig. 3. Localization of skeletal landmarks on both coronal and axial planes. (A) Assessment of the anterior expansion; (B) assessment of posterior expansion; (C) assessment of pterygoid expansion; (D) assessment of molar expansion and tipping

differences were evaluated with analysis of variance. T1–T0 differences of each measurement were used as independent variables, and the allocation group (RME vs. SME) was considered as

a factor. Significance level was set at $p < 0.05$. To calculate the method error and the intra-rater reliability, repeated measurements were collected in eight randomly selected patients (four RME and four SME) on two occasions separated by 1-week interval.

The method error (ME) for all the linear dental and skeletal measurements was assessed by means of the Dahlberg's formula $ME = (\sum d^2 / 2n)^{1/2}$, where d is the difference between the two measurements and n is the number of recordings. Pearson correlation coefficients were then calculated. Statistical analysis was performed by a single operator (IC), who was blinded to patient allocation (i.e., the allocation was masked to him in the dataset).

Results

Figure 4 demonstrates patient flow through the clinical trial.

CT data of 26 patients were analyzed, 12 (seven males, five females, mean age \pm SD: 10.3 ± 2.5 years) in the SME group and 14 (six males, eight females, mean age \pm SD: 9.7 ± 1.5 years) in the RME group. The error range of linear CT measurements was 0.5–0.7 mm. Pearson correlation coefficients ranged from 0.97 to 0.99.

Table 1 reports descriptive statistics and pairwise comparisons for T0 and T1 skeletal measurements. The groups were similar at baseline for all skeletal and dentoalveolar variables examined ($p > 0.05$). Maxillary expansion resulted in a significant increase in skeletal transverse widths at anterior, posterior, and pterygoid locations in both RME and SME groups. No side effects were experienced during the clinical phase, with the exception of a more painful response in RME patients. No appliance removal was required. No statistically significant differences between groups were found, with exception of the expansion measure at pterygoid processes, which was greater in the RME group (SME = 0.6 ± 0.6 mm, RME = 1.2 ± 0.9 mm, $p = 0.04$).

Table 2 reports descriptive statistics and pairwise comparison for T0 and T1 dental measurements. The appliance produced molar expansion at both cusp and apex levels in both

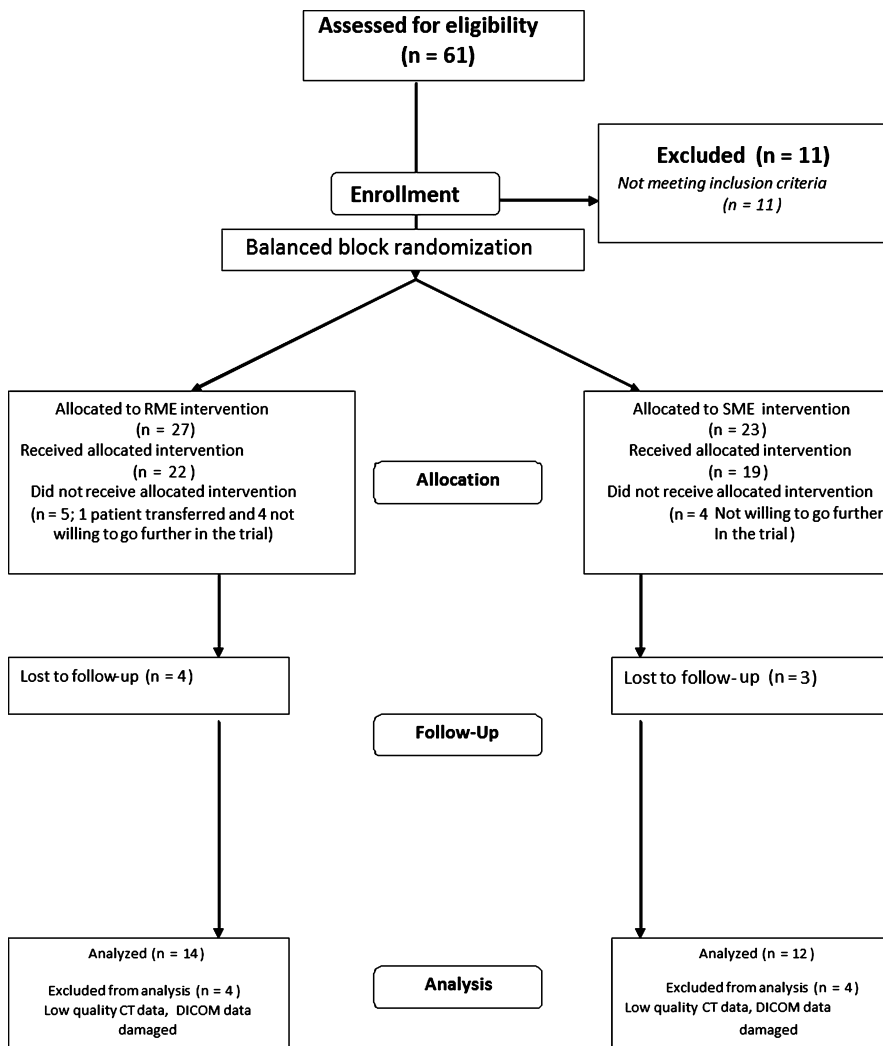


Fig. 4. Diagram of patient flow through the trial.

groups. In the SME group, molar tipping was not statistically significant (0.3 ± 0.9 mm), while in the RME group, there was negligible molar tipping (1.0 ± 1.2 mm, $p < 0.005$). The expansion measured at molar apices was significantly lower in the RME group than in SME group ($p = 0.02$).

Discussion

This study aimed to compare the skeletal and dento-alveolar effects of two palatal expansion procedures, RME and SME. To improve the precision of landmark identification and reduce the radiation exposure of the patients a low-dose CT protocol was used for research purposes (21). Thus, a comparison between the two expansion

modalities was possible using skeletal landmarks determined in three dimensions with much improved reproducibility and accuracy in comparison with posteroanterior radiographs (24), commonly used in previous research.

A two-band palatal expander was applied to perform the expansion. This appliance has been shown to be as effective as a four-band expander in increasing the transverse widths of maxillae in the long term (25, 26) and produces less patient discomfort with easier clinical management.

In this study, patients younger than 13 years were recruited, because the growth activity of the palatal suture has been reported to reduce around 14 years of age (27).

All patients were subjected to CT imaging before expansion and 7 months after initial activation of the appliances. This period was chosen to

Table 1. Descriptive statistics and pairwise comparisons for skeletal transverse changes measured in both groups

RME (<i>n</i> = 14) vs. SME (<i>n</i> = 12) skeletal transverse changes						
Skeletal transverse measurements	Group	T0 (mean ± SD)	T1 (mean ± SD)	T1-T0	SD	95% Confidence interval
Anterior expansion (mm)	SME	4.7 ± 1.9	6.6 ± 2.1	1.9	1.3**	1.0–2.1
	RME	5.8 ± 3.8	8.2 ± 4.4	2.5	1.5**	1.6–3.3
	Total			2.2	1.4	
Posterior expansion (mm)	SME	26.3 ± 2.2	28.2 ± 2.6	1.9	1.0**	1.3–2.5
	RME	26.2 ± 2.3	28.6 ± 2.6	2.4	0.9**	1.8–2.9
	Total			2.2	0.9	
Pterygoid expansion (mm)	SME	28.0 ± 2.1	28.6 ± 2.1	0.6 [†]	0.6*	0.2–1.0
	RME	28.0 ± 3.7	29.2 ± 4.2	1.2 [†]	0.9**	0.7–1.7
	Total			0.9	0.8	

Significant T1–T0 within-group differences are reported with asterisks (Significance level: **p* < 0.05, ***p* < 0.001).

[†]Significant differences between groups (slow maxillary expansion (SME) vs. rapid maxillary expansion (RME)). Values are in mm.

Table 2. Descriptive statistics and pairwise comparisons for dental transverse changes measured in both groups

Dental transverse measurements	Group	T0 (mean ± SD)	T1 (mean ± SD)	T1-T0 mean changes	SD	95% Confidence interval
Cr-CI (mm)	SME	37.2 ± 3.4	43.6 ± 4.5	6.3	2.1***	5.0–7.7
	RME	37.3 ± 1.8	43.0 ± 2.4	5.7	1.6***	4.8–6.7
	Total			6.0	1.8	
Ar-AI (mm)	SME	28.5 ± 3.0	34.5 ± 3.5	6.0	1.7***	4.9–7.0
	RME	28.6 ± 2.3	33.4 ± 2.6	4.7	1.2***	4.1–5.4
	Total			5.3	1.5	
Molar tipping (mm)	SME	8.8 ± 3.9	9.1 ± 4.1	0.3	0.9NS	0.2–0.9
	RME	8.6 ± 2.4	9.6 ± 2.6	1.0	1.2*	0.3–1.7
	Total			0.7	1.1	

Significant T1–T0 within-group differences are reported with asterisks (Significance level: **p* < 0.05, ***p* < 0.005, ****p* < 0.001, NS=not statistically significant). Values are in mm.

SME, slow maxillary expansion; RME, rapid maxillary expansion.

obtain proper remineralization of the mid-palatal suture and to reduce the risk of relapse (28, 29).

In both experimental groups, posterior crossbite was successfully treated, and a significant increase in the maxillary transverse widths of about 2.2 mm was obtained. The amount of palatal expansion did not differ significantly between the two investigated groups and was similar to previous findings (15, 20, 30). Nevertheless, the different imaging methodologies used in previously published studies (lateral radiograph and CT) as well as the use of

different landmarks do not allow for direct comparison of data between studies.

In a meta-analysis, Lagravere et al. examined clinical trials using 2D cephalometric analysis to evaluate the skeletal changes produced by RME (16). A pooled increase in the intermaxillary width of 1.88 mm was reported. Some of the studies analyzed (8, 25, 31–34) included subjects older than 14 years, that is, with reduced sutural growth activity (27). This might affect the amount of expansion reported in the meta-analysis (35).

An increase in transverse widths ranging from 1.6 (36) up to 2.6 mm (20) was found in studies using CT. Even among these studies, the use of different landmarks and the variation of patient age do not allow meaningful comparison. In the current study, the average increase in skeletal transverse widths between anterior and posterior locations was very similar and amounted to approximately 2.2 mm. This suggests that the expansion occurred homogeneously along the mid-palatal suture and contrasts with the 'V-shaped' maxillary expansion occurring with four bands or acrylic expanders (37). A possible explanation is the more posterior TBE line of action as compared with other appliances. This effect was more accentuated in the RME group, in which a statistically significant higher transverse expansion was measured at pterygoid locations.

Both expansion modalities produced increases in the molar transverse widths ranging from 4.7 to 6.3 mm, with no significant difference between the groups. These results are in agreement with data concerning RME by Lagraverè et al., who reported an average transverse increase of 6.7 mm at the crown level and 4.5 mm between molar crowns and molar apices (16). On the other hand, data from CT surveys reveal that the expansion measured at molar crowns ranged from 3.6 mm (36) to 8.9 mm (20) and that transverse widths measured between molar apices increased from 2.0 mm (36) to 6.8 mm (20).

In both groups, slight molar tipping was measured. The RME group showed a small (about 1 mm) but statistically significant molar tipping, which is in agreement with previous findings (38). In contrast, the tipping determined by SME was not statistically significant. The amount of tipping did not differ between groups, and the TBE appliance appeared to determine minor changes in the inclination of maxillary halves and molar teeth (38, 39). Buccal tipping is a common side effect of orthopedic expansion modalities and can

potentially be reduced using bonded instead of banded appliances (38, 39) because of the higher stiffness of bonded appliances.

Many authors report external root resorption in individuals undergoing RME (40–42) evaluated by scanning electron and light microscopy (41) and cone beam CT surveys (42). This resorption is likely a consequence of the great amount of cumulative forces produced by RME (28). Furthermore, higher pain rates have been reported in subjects who undergo maxillary expansion with two turns per day as compared to one turn per day (43). Unfortunately, root resorption and pain were not quantitatively assessed in the present study, but it was generally observed that RME patients reported higher levels of pain and discomfort than SME patients, especially during the initial activation.

In conclusion, this study demonstrated that SME is as effective as RME in determining skeletal transverse expansion of the maxilla in patients with a posterior crossbite. Slow maxillary expansion may be preferred to rapid maxillary expansion because of the reduced pain and discomfort. The long-term stability of the palatal expansion achieved needs to be evaluated.

Clinical relevance

The choice between rapid versus slow maxillary expansion still relies on clinical experience and attitude because of the lack of good scientific evidence (i.e. randomized controlled trials comparing the two treatment modalities). This study aimed to compare the transverse effects produced by the two maxillary expansion modalities to allow orthodontists to make evidence-based treatment decisions.

Acknowledgements: The manuscript was supported by a grant of the Italian Ministry of University and Research (MIUR Protocol Number: 2005069705). A special thanks to Dr Ali Ukra for editing the manuscript.

References

1. Thilander B, Wahlund S, Lennartsson B. The effect of early interceptive treatment in children with posterior crossbite. *Eur J Orthod* 1984;6:25–34.
2. Ciuffolo F, Manzoli L, D'Attilio M, Tecco S, Muratore F, Festa F et al. Prevalence and distribution by gender of occlusal characteristics in a sample of Italian secondary school students: a cross-sectional study. *Eur J Orthod* 2005;27:601–6.
3. Garrett BJ, Caruso JM, Rungcharassaeng K, Farrage JR, Kim JS, Taylor GD. Skeletal effects to the maxilla

- after rapid maxillary expansion assessed with cone-beam computed tomography. *Am J Orthod Dentofacial Orthop* 2008;134:8–9.
4. Baccetti T, Mucedero M, Leonardi M, Cozza P. Interceptive treatment of palatal impaction of maxillary canines with rapid maxillary expansion: a randomized clinical trial. *Am J Orthod Dentofacial Orthop* 2009;136:657–61.
 5. Kiki A, Kiliç N, Oktay H. Condylar asymmetry in bilateral posterior crossbite patients. *Angle Orthod* 2007;77:77–81.
 6. Andrade AS, Gameiro GH, Derossi M, Gavião MB. Posterior crossbite and functional changes. A systematic review. *Angle Orthod* 2009;79:380–6.
 7. Hass AJ. Palatal expansion: just the beginning of dentofacial orthopedics. *Am J Orthod Dentofacial Orthop* 1970;57:219–55.
 8. Asanza S, Cisneros GJ, Nieberg LG. Comparison of Hyrax and bonded expansion appliances. *Angle Orthod* 1997;67:15–22.
 9. Huynh T, Kennedy DB, Joondeph DR, Bollen AM. Treatment response and stability of slow maxillary expansion using Haas, hyrax, and quad-helix appliances: a retrospective study. *Am J Orthod Dentofacial Orthop* 2009;136:331–9.
 10. Mutinelli S, Cozzani M, Manfredi M, Bee M, Siciliani G. Dental arch changes following rapid maxillary expansion. *Eur J Orthod* 2008;30:469–76.
 11. Marini I, Bonetti GA, Achilli V, Salemi G. A photogrammetric technique for the analysis of palatal three-dimensional changes during rapid maxillary expansion. *Eur J Orthod* 2007;29:26–30.
 12. Cao Y, Zhou Y, Song Y, Vanarsdall RL Jr. Cephalometric study of slow maxillary expansion in adults. *Am J Orthod Dentofacial Orthop* 2009;136:348–54.
 13. Gracco A, Malaguti A, Lombardo L, Mazzoli A, Raffaelli R. Palatal volume following rapid maxillary expansion in mixed dentition. *Angle Orthod* 2010;80:153–9.
 14. Schiffman PH, Tuncay OC. Maxillary expansion: a meta analysis. *Clin Orthod Res* 2001;4:86–96.
 15. Lagravere MO, Major PW, Flores-Mir C. Long-term skeletal changes with rapid maxillary expansion: a systematic review. *Angle Orthod* 2005;75:1046–52.
 16. Lagravere MO, Heo G, Major PW, Flores-Mir C. Metaanalysis of immediate changes with rapid maxillary expansion treatment. *J Am Dent Assoc* 2006;137:44–53.
 17. Diederichs CG, Engelke WG, Richter B, Hermann KP, Oestmann JW. Must radiation dose for CT of the maxilla and mandible be higher than that for conventional panoramic radiography? *AJNR Am J Neuroradiol* 1996;17:1758–60.
 18. Mozzo P, Procacci C, Tacconi A, Tinazzi Martini P, Bergamo Adnreis IA. A new volumetric CT machine for dental imaging based on the cone-beam technique: preliminary results. *Eur Radiol* 1998;8:1558–64.
 19. Nakajima A, Sameshima GT, Arai Y, Homme Y, Shimizu N, Dougherty H Sr. Two and three-dimensional orthodontic imaging using limited cone beam-computed tomography. *Angle Orthod* 2005;75:895–903.
 20. Garib DG, Henriques JF, Janson G, Freitas MR, Coelho RA. Rapid maxillary expansion – tooth tissue-borne versus tooth-borne expanders: a computed tomography evaluation of dentoskeletal effects. *Angle Orthod* 2005;75:548–57.
 21. Matarese G, Portelli M, Mazza M, Militi A, Nucera R, Gatto E et al. Evaluation of skin dose in a low dose spiral CT protocol. *Eur J Paediatr Dent* 2006;7:77–80.
 22. Ballanti F, Lione R, Fanucci E, Franchi L, Baccetti T, Cozza P. Immediate and post-retention effects of rapid maxillary expansion investigated by computed tomography in growing patients. *Angle Orthod* 2009;79:24–9.
 23. Ballanti F, Lione R, Baccetti T, Franchi L, Cozza P. Treatment and posttreatment skeletal effects of rapid maxillary expansion investigated with low-dose computed tomography in growing subjects. *Am J Orthod Dentofacial Orthop* 2010;138:311–7.
 24. Leonardi R, Annunziata A, Caltabiano M. Landmark identification error in posteroanterior cephalometric radiography. A systematic review. *Angle Orthod* 2008;78:761–5.
 25. Lamparski DG Jr, Rinchuse DJ, Close JM, Sciote JJ. Comparison of skeletal and dental changes between 2-point and 4-point rapid palatal expanders. *Am J Orthod Dentofacial Orthop* 2003;123:321–8.
 26. Davidovitch M, Efstathiou S, Same O, Vardimon AD. Skeletal and dental response to rapid maxillary expansion with 2- versus 4-band appliances. *Am J Orthod Dentofacial Orthop* 2005;127:483–92.
 27. Melsen B. Palatal growth studied on human autopsy material. A histologic microradiographic study. *Am J Orthod* 1975;68:42–54.
 28. Isaacson RJ, Wood JL, Ingram AH. Forces produced by rapid maxillary expansion. *Angle Orthod* 1964;34:256–70.
 29. Ekström C, Henrikson CO, Jensen R. Mineralization in the midpalatal suture after orthodontic expansion. *Am J Orthod* 1977;71:449–55.
 30. Kartalian A, Gohl E, Adamian M, Enciso R. Cone-beam computerized tomography evaluation of the maxillary dentoskeletal complex after rapid palatal expansion. *Am J Orthod Dentofacial Orthop* 2010;138:486–92.
 31. Almeida G, Capeloza Filho L, Trindade ASJ. Rapid maxillary expansion: a prospective study. *Ortodontia* 1999;32:45–56.
 32. Kawakami RY, Henriques JFC, Pinzan A, de Freitas MR, Janson G. Comparison of dentoskeletal effects produced by two types of rapid maxillary expansion appliances by means of lateral cephalometric evaluation. *Ortodontia* 1999;32:8–27.
 33. Faltin KJ, Moscatiello VA, Barrios EC. Faltin Jr's palatal expander: dentofacial changes resulting from rapid maxillary expansion. *Rev Dent Press Ortodont Ortopedi Facial* 1999;4:5–13.
 34. Mazziero ET, Henriques JFC, Freitas MR. Study of frontal cephalometric dentoskeletal changes after the rapid maxillary expansion. *Ortodontia* 1996;29:31–42.
 35. Baccetti T, Franchi L, Cameron CG, McNamara JA Jr. Treatment timing for rapid maxillary expansion. *Angle Orthod* 2001;73:343–50.
 36. Podesser B, Williams S, Crismani AG, Bantleon HP. Evaluation of the effects of rapid maxillary expansion in growing children using computer

- tomography scanning: a pilot study. *Eur J Orthod* 2007;29:37–44.
37. Wertz R, Dreskin M. Midpalatal suture opening: a normative study. *Am J Orthod* 1977;71:367–81.
38. Kiliç N, Kiki A, Oktay H. A comparison of dentoalveolar inclination treated by two palatal expanders. *Eur J Orthod* 2008;30:67–72.
39. Olmez H, Akin E, Karaçay S. Multitomographic evaluation of the dental effects of two different rapid palatal expansion appliances. *Eur J Orthod* 2007;29:379–85.
40. Barber AF, Sims MR. Rapid maxillary expansion and external root resorption in man: a scanning electron microscope study. *Am J Orthod* 1981;79:630–52.
41. Langford SR, Sims MR. Root surface resorption, repair, and periodontal attachment following rapid maxillary expansion in man. *Am J Orthod* 1982;81:108–15.
42. Baysal A, Karadede I, Hekimoglu S, Ucar F, Ozer T, Veli I et al. Evaluation of root resorption following rapid maxillary expansion using cone-beam computed tomography. *Angle Orthod*. 2011; doi 10.2319/060411-367.1.
43. Needleman HL, Hoang CD, Allred E, Hertzberg J, Berde C. Reports of pain by children undergoing rapid palatal expansion. *Pediatr Dent* 2000;22: 221–6.